

Functional Morphology of the Pharyngeal Jaw Apparatus in Moray Eels

Rita S. Mehta* and Peter C. Wainwright

Section of Evolution and Ecology, University of California, Davis, California 95616

ABSTRACT Moray eels (Muraenidae) are a relatively large group of anguilliform fishes that are notable for their crevice-dwelling lifestyle and renowned for their ability to consume large prey. Morays apprehend their prey by biting and then transport prey by extreme protraction and retraction of their pharyngeal jaw apparatus. Here, we present a detailed interpretation of the mechanisms of pharyngeal jaw transport based on work with *Muraena retifera*. We also review what is known of the moray pharyngeal jaw apparatus from the literature and provide comparative data on the pharyngeal jaw elements and kinematics for other moray species to determine whether interspecific differences in morphology and behavior are present. Rather than comprising broad upper and lower processing tooth plates, the pharyngeal jaws of muraenine and uropterygiine morays, are long and thin and possess large, recurved teeth. Compared with the muraenines, the pharyngobranchials of the uropterygiines do not possess a horn-shaped process and their connection to the fourth epibranchial is dorsal rather than medial. In addition, the lower tooth plates do not exhibit a lateral groove that serves as a site of muscle attachment for the pharyngocleitheralis and the ventral rather than the lateral side of the lower tooth plate attaches to the fourth ceratobranchial. In all morays, the muscles positioned for protraction and retraction of the pharyngeal apparatus have undergone elongation, while maintaining the generalized attachment sites on the bones of the skull and axial skeleton. Uropterygiines lack a dorsal retractor muscle and we presume that retraction of the pharyngeal jaws is achieved by the pharyngocleitheralis and the esophagus. The fifth branchial adductor is greatly hypertrophied in all species examined, suggesting that morays can strongly adduct the pharyngeal jaws during prey transport. The kinematics of biting behavior during prey capture and transport resulted in similar magnitudes of cranial movements although the timing of kinematic events was significantly different and the duration of transport was twice as long as prey capture. We speculate that morays have evolved this alternative prey transport strategy as a means of overcoming gape constraints, while hunting in the confines of coral reefs. *J. Morphol.* 269:604–619, 2008. © 2008 Wiley-Liss, Inc.

KEY WORDS: moray eel; intra-oral transport; pharyngeal jaw apparatus; functional innovation

The Elopomorpha is a relatively large and early radiation of teleost fishes comprising species as diverse as tarpon, bonefish, halosaurs, spiny eels, and anguilliform eels (Nelson, 2006). Anguilliform

eels comprise roughly 95% of the taxonomic diversity and species richness within the Elopomorpha. Muraenids, otherwise known as moray eels, are a clade within the anguilliforms. They include roughly 200 species and represent one of the largest clades within the anguilliforms. Within the muraenids, two monophyletic subgroups are recognized: Uropterygiinae and Muraeninae. These subgroups are based on morphological characters of the gill arch region and the development of the median fin (Böhlke et al., 1989). Uropterygiines contain the genera *Anarchias*, *Channomuraena*, *Scuticaria*, and *Uropterygius*, while roughly twelve genera are thought to comprise the muraenines (see McCosker and Randall, 2007 for new genus, *Diaphenchelys*).

In addition to being extremely elongate with a reduced cross-sectional area, a body plan that is shared by all anguilliform fishes, morays exhibit many morphological specializations for a crevice dwelling lifestyle such as the absence of scales, the ability to exude copious amounts of body mucus (Randall et al., 1981), the loss of pectoral and pelvic fins (Böhlke et al., 1989), gill arch reduction and extreme posterior placement of the gill arches (Nelson, 1966). These additional characteristics appear to allow morays to effectively move and hunt in the crevices of coral heads and rocky reefs. Unlike the majority of anguilliforms, some species of morays can attain standard lengths of up to 3.9 m (Myers, 1991). The ability of morays to attain great size is ecologically interesting, especially in light of their high density that has been reported in certain areas in the Caribbean (Randall, 1963; Gilbert et al., 2005). Surveys in the Virgin Islands (Randall, 1963) and those that took place recently in Barbados (Gilbert et al., 2005), suggest that

Contract grant sponsor: NSF; Contract grant number: IOB-0444554; Contract grant sponsor: American Association of University Women (AAUW) Fellowship.

*Correspondence to: Rita S. Mehta, Section of Evolution and Ecology, University of California, One Shields Ave, Davis, CA 95616. E-mail: rsmehtha@ucdavis.edu

Published online 14 January 2008 in Wiley InterScience (www.interscience.wiley.com) DOI: 10.1002/jmor.10612

muraenids exhibit an average density of 5.6 fish per 125 m⁻², which is similar to that of other large predatory fishes for which densities have been examined (Randall, 1963). Although morays are known to feed on relatively large prey, dietary accounts in the literature are sparse and few studies document prey consumed in relation to the size of the predator (Randall, 1967; Yukihiro et al., 1994; Young and Winn, 2003). How a relatively large aquatic predator with a reduced cross-sectional area, a large gape, and a noncircular mouth opening can consume large prey is interesting from a biomechanical, physiological, and ecological perspective.

In recent studies, we explored the functional morphology of prey capture and transport in moray eels noting the marked reduction in moveable cranial elements and the small size of the hyoid bar, which are key characteristics of many suction-feeding fishes. We tested the effects of these reduced cranial elements on feeding kinematics and concluded that morays do not use suction to capture prey, but rather, apprehend prey with a bite (Mehta and Wainwright, 2007a). Although other groups of teleosts are known to apprehend prey by direct biting rather than by inertial suction feeding (Lauder, 1980a,b; Lauder and Norton, 1980; Alfaro et al., 2001; Porter and Motta, 2004; Janovetz, 2005; Konow and Bellwood, 2005) subsequent transport behaviors still involve hydraulic, suction-based mechanisms (e.g., Lauder, 1983). We discovered that moray eels have evolved an alternative mechanism of prey transport that involves extreme movement of their pharyngeal jaw region and we speculate that this novel function enables morays to effectively swallow large prey (Mehta and Wainwright, 2007b). However, not all morays are known to consume large prey. In fact, many morays feed mainly on crustaceans and other soft and hard-shelled invertebrates (Myers, 1991). This variation in dietary patterns, in addition to the morphology-based sub-groupings of morays (Uropterygiines and Muraenines) suggests diverse selection pressures in nature that may affect pharyngeal jaw characteristics.

Inspired by the cranial design of moray eels and intrigued by their novel prey transport behavior, we studied the design of the pharyngeal jaws in a variety of moray species. The purpose of our study was first to provide a general description of the anatomy of the moray pharyngeal jaw apparatus. We examine pharyngeal jaw diversity by looking across genera. We also discuss the characteristics that contribute to interspecific differences and note if our observations differ from those already in the literature. Secondly, we provide a detailed analysis of protraction and retraction of the pharyngeal jaws during transport. In doing so, we offer a unifying terminology for some of the branchial muscles underlying this important behavior

pattern, following Winterbottom (1974). We also examine the kinematics of biting behavior in morays and use *Muraena retifera* as our model for understanding the kinematic differences between oral jaw biting during prey capture and transport. On the basis of anatomical characters and functional data for *Muraena retifera* and feeding observations for three other species, we make generalizations concerning the degree to which different morays use their pharyngeal jaws during transport. Lastly, we point out the skeletal changes that occurred that enabled the significant increase in protraction distance in the pharyngeal jaw apparatus of morays and discuss how this pharyngeal innovation may be an adaptation for feeding in the confines of coral reefs.

MATERIALS AND METHODS

We studied the morphology and kinematics of the reticulated moray eel, *Muraena retifera* (Goode and Bean). Four adult *Muraena retifera* (Standard Lengths 35.5, 37.2, 34.32, and 40.3 cm) were obtained commercially from Forest Young of Dynasty Marine Associates in the Florida Keys. We recorded video of feeding behavior for these individuals. After all kinematic sequences were obtained, the specimens were formalin-fixed and used to examine the morphology and anatomy related to the pharyngeal jaw apparatus. Two specimens were cleared and double-stained for cartilage (Alcian blue) and bone (Alizarin red S) following a modification of Dingerkus and Uhler (1977). Specimens were examined with a Wild Heerbrugg dissecting microscope. Following staining, the pharyngeal jaw apparatus of one of these specimens was disarticulated for photographs with a digital Canon EOS. One formalin-fixed individual was X-rayed and the radiograph was also used to examine the resting position of the pharyngeal jaws in relation to the skull. In addition to the specimens of *Muraena retifera*, we studied preserved specimens and cleared and stained specimens of two uropterygiines: *Anarchias seychellensis* (Smith) ($N = 2$) and *Uropterygius macrocephalus* (Bleeker) ($N = 3$) and the following eight muraenines: *Echidna catenata* (Bloch) ($N = 2$), *Echidna nebulosa* (Ahl) ($N = 3$), *Echidna rhodochilus* (Bleeker) ($N = 4$), *Enchelycore bayeri* (Schultz) ($N = 2$), *Gymnothorax funebris* (Ranzani) ($N = 2$), *Gymnothorax javanicus* (Bleeker) ($N = 4$), *Gymnomuraena zebra* (Shaw) ($N = 3$), and *Rhinomuraena quaesita* (Garman) ($N = 3$).

Videofluoroscopy at the University of California Center for Imaging Sciences, Davis was used to analyze the full range of motion of the pharyngeal jaws of a single individual of *Muraena retifera* and *Gymnothorax funebris*. Each moray was placed in a 25-l glass aquarium and was filmed at 30 images s⁻¹, while consuming a single goldfish, *Carassius auratus*, that was soaked in sixty percent w/v liquid barium sulfate (Novopaque, LPI Diagnostics, Yorba Linda, CA.).

Functional Morphology of the Pharyngeal Jaw Apparatus

We examined high-speed videos of moray eels to investigate the role of the pharyngeal jaw apparatus during feeding. Individuals of *Muraena retifera* were filmed feeding on pieces of cut squid (*Loligo* sp.), 2.36 ± 0.14 cm in width. We also observed three individuals of *Echidna nebulosa* and *Echidna rhodochilus* feeding on pieces of cut squid and earth worms (*Lumbricus* sp.), and two individuals of *Gymnothorax funebris* feeding on small and large goldfish (*Carassius* sp.). Although we did not analyze the feeding kinematics from the feeding videos acquired for these species, observations of their transport behavior provided

important insight on the different kinematic variables that could be included in our data set.

All morays were housed and filmed at 22–27°C in 100-l aquaria at the University of California, Davis using a NAC Memrecam ci digital system with illumination from two 600-W flood lights. Video sequences were recorded at 100 images s⁻¹. Distances in the images were scaled by recording an image of a ruler placed in the field of view. We analyzed only those sequences in which a lateral view of the fish could clearly be seen in the image and the head of the fish was oriented approximately perpendicular to the camera. All procedures and methods used were included in a research protocol that was approved by the UC Davis IACUC committee.

A total of 65 prey transport sequences were analyzed, with a minimum sample size of 12 for each individual of *Muraena retifera*. To quantify intra-oral prey transport, we analyzed images from the video sequences with the aid of Scion Image software. We measured the x, y coordinates of nine landmarks from the images: i) the anterior tip of the premaxilla (upper jaw), ii) anterior tip of the dentary (lower jaw), iii) corner of the mouth, iv) anterior end of upper pharyngeal jaw when visible, v) estimated position of the neurocranium-vertebral joint, vi) anterior-most point of the orbit, vii) reference point on the body, viii) posterior end of the branchial basket where it bulged laterally against the skin of the pharynx, and (ix) estimated center of mass of the prey once in the oral cavity. Coordinates of these landmarks were measured at six points in time: onset of the strike characterized by the onset of fast lower jaw rotation; time of peak gape; time of prey capture; defined as the frame in which the upper and lower jaws made contact with the prey; time of appearance of pharyngeal jaws; time when the pharyngeal jaws contacted the prey; and onset time of prey movement. From each prey capture sequence, we determined maximum gape distance preceding prey capture, pharyngeal jaw protraction distance, distance the head retracted/body advanced during pharyngeal protraction, cranial excursion during pharyngeal protraction, and the rate of prey movement during swallowing (cm/s).

Of the 65 sequences, 41 (10–11 from each individual) were complete feeding sequences beginning with prey capture and ending with transport. From each complete feeding sequence, the following nine variables were derived and calculated for each capture and transport event (all timing variables were measured relative to time 0, defined as the onset of the strike, characterized by fast lower jaw depression, and were accurate to the nearest 5 ms): i) peak gape distance (cm), ii) time of peak gape distance (s), iii) peak cranial elevation (degrees), iv) time of peak cranial elevation (s), v) peak jaw excursion (degrees), vi) time of peak jaw excursion (s), vii) time of prey capture(s), viii) ventral displacement (cm), and ix) time of peak ventral displacement (s). Capture time was defined as the time when the oral jaws (both upper and lower jaw) came in contact with the prey during the prey capture phase. During the transport phase, capture time was the time the pharyngeal jaws made contact with prey.

Statistical Analyses

Basic statistics were calculated for the kinematic variables measured and all data were log transformed to meet the assumptions of normality. A two-way mixed-model analysis of variance (ANOVA) was used with behavior (capture vs transport) as the fixed effects and individual as a between-subjects effect to test for differences in the nine kinematic variables that could be measured during both prey capture and transport. To account for multiple tests, the level of significance was adjusted using the sequential Bonferroni adjustment technique described by Rice (1989).

To examine multivariate kinematic differences in prey capture and prey transport, we performed a principle components analysis (PCA) on capture and transport variables. Nine principle components were extracted from a correlation matrix; their component loadings were examined, and factor scores for the first two principle components explaining the most variation

were plotted against one another. We used SPSS version 13.0 (SPSS, Chicago, IL) for all statistical analyses.

RESULTS

Branchial Arches and Pharyngeal Jaws

The branchial arches of *Muraena retifera* are posteriorly displaced compared with the branchial arches of generalized elopomorphs (see Fig. 1). In *Megalops*, the gill arches are located just posterior to the orbit and within the posterior part of the neurocranium, representing a condition also common among percormorphs. In *Elops*, the gill arches are more posteriorly placed that may have to do with the overall lengthening of the neurocranium. As noted in an earlier study (Nelson, 1966), the posterior displacement of the branchial arch elements is a characteristic trend within anguilliforms. Muraenids, however, exhibit an extreme condition as revealed by *Muraena retifera* (Fig. 1C) and other morays examined in this study.

Four bilaterally paired branchial arches and their gill filaments are present in *Muraena retifera*. Gill rakers are absent (Böhlke et al., 1989) and the gill arches are greatly reduced (Nelson, 1966). The dorsal gill arch elements comprise four-paired epibranchials. The basibranchials and hypobranchials of the ventral gill arches are absent and only ceratobranchials 1–4 are present in muraenines. Although the basibranchials are absent, the hypobranchials on the first and second gill arch elements are ossified in the uropterygiines, *Anarchias seychellensis* and *Uropterygius macrocephalus*.

In most teleosts, the pharyngeal jaws are modifications of the fourth and fifth branchial arches. The pharyngeal jaws of morays are modifications of the fourth branchial arch and the fifth arch is lost (Popta, 1904; Nelson, 1966, 1967). The pharyngeal jaw apparatus is well-developed in all morays examined and the skeletal elements of the pharyngeal jaws included the only bones that were easily discernible in radiographs (see Fig. 2). The fourth epibranchial is the largest of the dorsal gill arch bones and the most posteriorly placed. It is long and thin but widens where it connects to the fourth ceratobranchial element. The most anterior portion of the fourth epibranchial is connected to the center of a well-developed fourth pharyngobranchial bone, which is endowed with two rows of 14–16 sharply recurved teeth (see Fig. 3). The dorsal portion of fourth pharyngobranchial has a distinctive horn-shaped process in muraenines. The anterior portion of the fourth epibranchial attaches to the medial side of the process. Movement at this joint between the fourth pharyngobranchial and the fourth epibranchial allows dorsal-ventral movement of the anterior end of the fourth pharyngobranchial and its teeth (Figs. 3 and 4A,B). In uropterygiines, the dorsal portion of the fourth pharyngobranchial attaches to the epibranchial

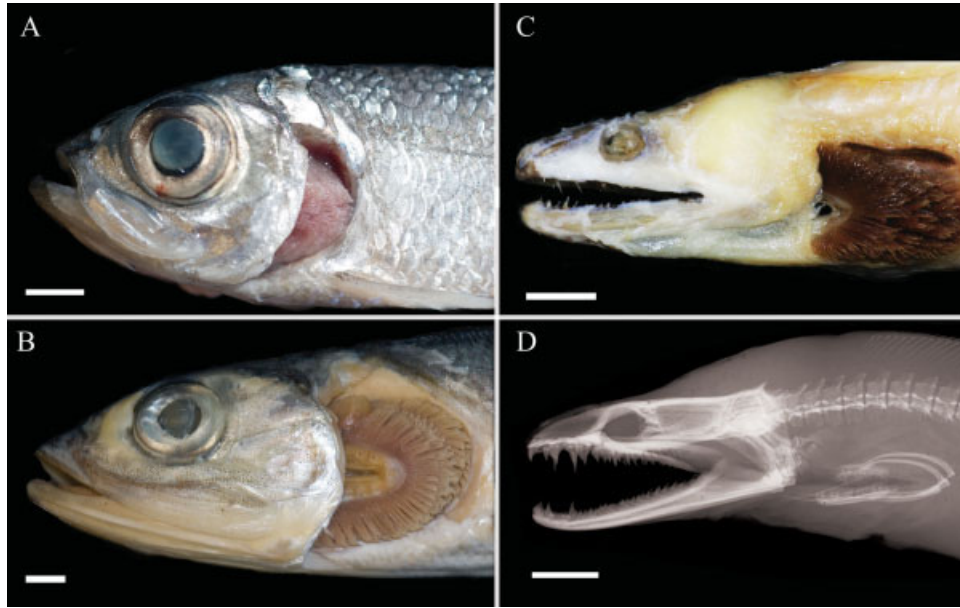


Fig. 1. Photographs depicting gill arch placement for three species of elopomorphs in lateral view. The opercle has been removed in specimens A and B to show the gill filaments. **A:** The gill arches of *Megalops cyprinoides* are directly behind the orbit, representing the most common gill arch position in teleosts. **B:** The gill arches of *Elops saurus* are slightly displaced posteriorly. This posterior placement is presumably related to the lengthening of the neurocranium and mild body elongation in this genus. **C:** The gill arches of *Muraena retifera*. Note the extreme posterior placement of the gill arches in relation to the neurocranium. The specimen has been skinned to expose the general anatomy of the neurocranium. **D:** A radiograph of the same specimen in C revealing the well-developed fourth branchial arch that forms the pharyngeal jaws, and its posterior position. Scale bars = 1 cm.

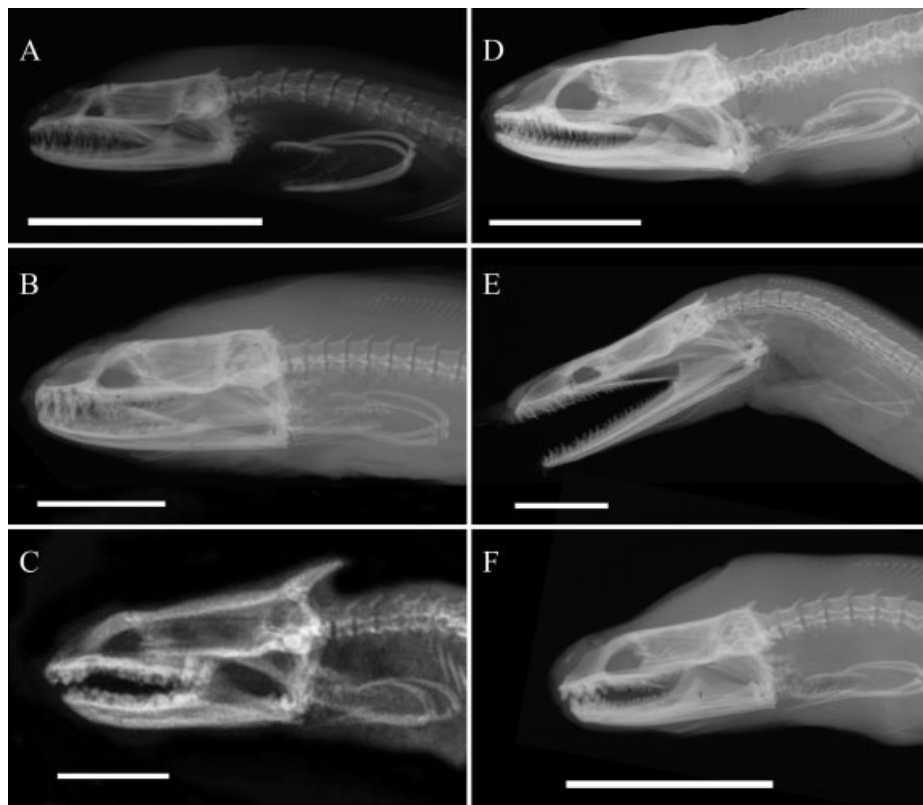


Fig. 2. Radiographs depicting the well-developed pharyngeal jaw apparatus of moray eels. **A:** *Anarchias seychellensis* (Uropterygiinae). **B:** *Gymnothorax javanicus* (Muraeninae). **C:** *Gymnomuraena zebra* (Muraeninae). **D:** *Uropterygius macrocephalus* (Uropterygiinae). **E:** *Rhinomuraena quaesita* (Muraeninae). **F:** *Echidna nebulosa* (Muraeninae). Scale bar = 1 cm.

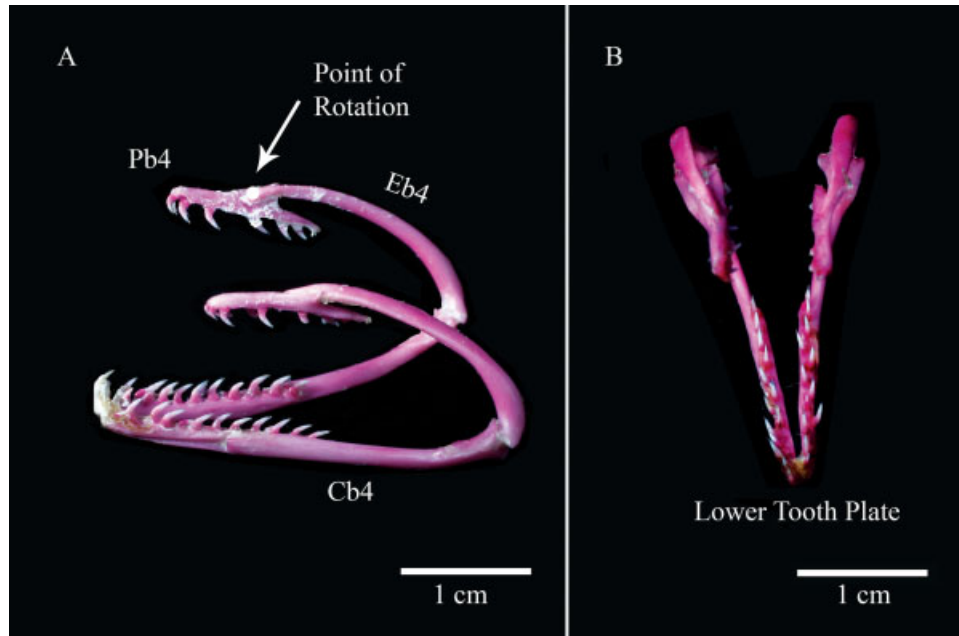


Fig. 3. Photographs depicting the pharyngeal jaw apparatus of a representative muraenine, *Muraena retifera*, in lateral and dorsal views. Jaws were stained with alizarin red and removed from a cleared and stained specimen for digital photographs. Pb4, 4th pharyngobranchial; Eb4, 4th epibranchial; Cb4, 4th ceratobranchial. **A:** Eb4 and Cb4 are elongate and thin bony elements. The fourth pharyngobranchial has a horn-shaped process and the medial side of this process is the attachment site for Eb4. The teeth on the upper and lower pharyngeal tooth plates are long and highly recurved. **B:** The dorsal view reveals the anterior connection of the lower pharyngeal tooth plates as well as the narrow design of the pharyngeal jaw apparatus.

rather than the medial side. Also, the fourth pharyngobranchial does not exhibit a prominent horn but a less raised process is present.

The fourth ceratobranchial is the largest of the ventral gill arches. As noted in earlier studies (Popta, 1904; Nelson, 1966; Böhlke et al., 1989), the fifth ceratobranchial is lost. The lower pharyngeal tooth plate is elongate and contains two rows of recurved teeth. There is a deep groove on the lateral surface of the lower pharyngeal tooth plate, onto which the fourth ceratobranchial connects in all muraenines. Nelson (1966) noted that the nine uropterygiine species he examined lack a groove on their lower tooth plate. The lateral side of the lower pharyngeal tooth plates of the two species we examined, *Anarchias seychellensis* and *Uropterygius macrocephalus*, were not grooved, supporting Nelson's observations.

In muraenines, roughly 1/3 of the lower pharyngeal tooth plate attaches medially to the anterior portion of the fourth ceratobranchial (Figs. 3 and 4A,B). In uropterygiines, the ventral side of the lower tooth plate attaches to the dorsal side of the fourth ceratobranchial. The anteriormost region of the left and right lower pharyngeal tooth plate is joined medially by connective tissue in both conditions. In contrast to the pharyngeal tooth plates of most teleosts, those of *Muraena retifera* and other morays are elongate and appear to be specialized for grasping prey.

The displacement of the pharyngeal jaws appears to differ across moray species. We attempted to quantify this difference in pharyngeal position by noting the position of the posterior portion of the pharyngeal jaw in relation to the vertebral column in cleared and stained specimens. The posterior portion of the pharyngeal jaw was determined by referencing the joint between the epibranchial and ceratobranchial. In the morays examined, this connection lies ventral to vertebrae 8–13. No intraspecific differences were observed. The pharyngeal jaws of *Muraena retifera* are positioned below the ninth vertebrae, while the pharyngeal jaws of *Rhinomuraena quaesita* exhibit the most displaced position, sitting just below vertebrae 13 (see Fig. 5). The posterior part of the pharyngeal jaws for *Gymnomuraena zebra* was below vertebrae 7, while the pharyngeal jaws of *Anarchias seychellensis*, *Uropterygius macrocephalus*, *Echidna catenata*, *Echidna nebulosa*, and *Echidna rhodochilus* were located below vertebrae 8. The strongly piscivorous morays that we examined, *Muraena retifera*, *Gymnothorax funebris*, and *Gymnothorax javanicus*, had their pharyngeal jaws positioned below vertebrae 9.

Muscles of the Pharyngeal Jaw Apparatus

There has been some confusion pertaining to gill arch muscle terminology, in addition to which

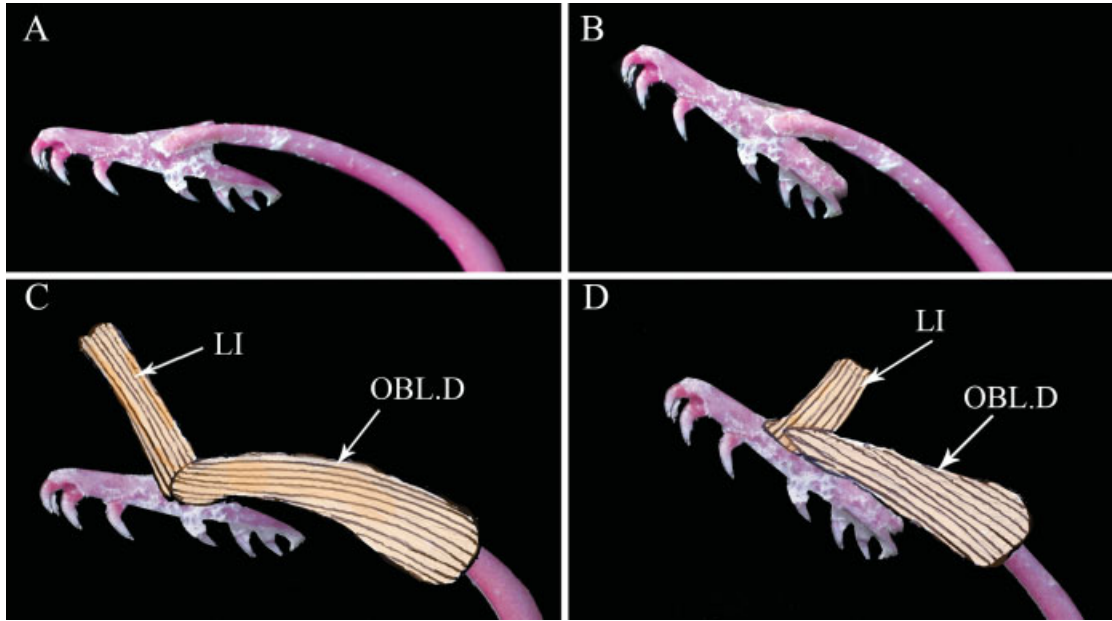


Fig. 4. Photographs depicting the pharyngeal jaw apparatus of the muraenine, *Muraena retifera* in medial view. **A:** The horn-shaped process and the medial attachment site for the fourth epibranchial are shown. **B:** The pharyngobranchial dorsally rotates at the pharyngobranchial/epibranchial (PB4/Eb4) joint to ensnare prey. **C:** The levator internus 4 originates on the parasphenoid and inserts onto the posterior portion of the dorsal side of the fourth epibranchial. The obliquus dorsalis spans the pharyngobranchial and the epibranchial. **D:** Contraction of the levator internus 4 or the obliquus dorsalis can dorsally rotate the pharyngobranchial.

muscles are responsible for moving the moray pharyngeal jaw apparatus. Synonyms for moray gill arch and pharyngeal muscles were compiled from the literature and identified following Winterbot-

tom (1974). Muscle terminology is presented in Table 1.

Dorsal muscles. The dorsal branchial levators are the only muscles that connect the pharyngeal jaw apparatus to the neurocranium. The muscle fibers of the external and internal dorsal branchial levators are extremely elongate compared with other teleosts for which branchial muscles have been previously described. In muraenines, four external levators (1–4) are present. Levator externi 1–4 have their sites of insertion on the dorsal surface of the corresponding epibranchials (1–4) resulting in more posterior muscles being longer than more anterior muscles. Levator externus 4, the longest, runs dorsally along the epibranchial bone and inserts on the posterior portion of the

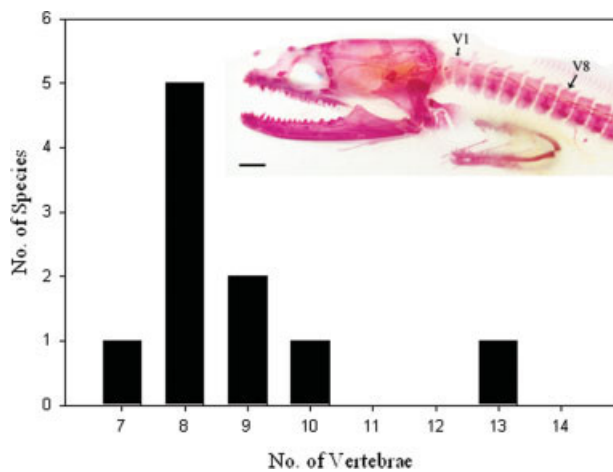


Fig. 5. A histogram depicting the variation in location of the fourth branchial arch in morays. *Anarchias seychellensis* is used to illustrate how we determined where the pharyngeal jaws sit in relation to the vertebral column. The pharyngeal jaws of the uropterygiines and all durophagous morays were positioned below vertebrae 7 or 8, while the pharyngeal jaws of the strongly piscivorous morays had their pharyngeal jaws positioned below vertebrae 9. The pharyngeal jaws of *Rhinomuraena quaesita* exhibited the most extreme condition and was positioned below vertebrae 13.

TABLE 1. Muscle terminology adopted from Winterbottom (1974) and Springer and Johnson (2004)

Adopted Terminology (Winterbottom, 1974)	Synonyms (Nelson, 1967)
Dorsal muscles of the 4th gill arch element	
Levator externus 4	Protractor posterior
Internal levator 4	Protractor medialis
Obliquus dorsalis	Obliquus inferior, superior
Adductor 5	Obliquus posterior
Dorsal retractor	Lateral retractor
Ventral muscles of the 4th gill arch element	
Pharyngocleithralis	Pharyngoclavicularis
Rectus communis	Ventral retractor

dorsal side of the fourth epibranchial. The external levators converge to form a single bundle of muscle fibers just below the origination site on the parasphenoid. There is a single internal branchial levator, levator internus 4, that originates from the posterior part of the parasphenoid just behind the bundle of levator externi and inserts on the dorsal side of the fourth pharyngobranchial just anterior to the Pb4/Eb4 joint (Fig. 4C). The internal and external levators have an anterior–posterior as well as a dorsal–ventral line of action.

In uropterygiines, the branchial levators are extremely reduced. The internal levators 1–3 are lost. As in the muraenine condition, there is a single internal branchial levator, levator internus 4, that originates from the posterior part of the parasphenoid and inserts on the dorsal side of the fourth pharyngobranchial just anterior to the Pb4/Eb4 joint. The external levators 1–2 are lost and levator externus 3 is very reduced. Levator externus 4 is well-developed. The levator externi 3 and 4 insert onto the dorsal arm of the epibranchial and attach onto the parasphenoid. Rather than form a bundle with levator externus 4, levator externus 3 runs along side it.

Two of the internal muscles of the fourth gill arch are greatly hypertrophied (see Fig. 6). The obliquus dorsalis, which medially spans the joint between the fourth epibranchial and the fourth pharyngobranchial is well-developed. Adductor 5 is a very large muscle that originates on the postero-medial face of the fourth epibranchial and connects to the posterodorsal end of the fourth ceratobranchial.

The esophagus, which separates the right and left sides of the pharyngeal arms, extends medially to reach the fourth pharyngobranchial and the lower pharyngeal tooth plate. From a sagittal section, it is apparent that the posterior ends of the left and right sides of the pharyngeal jaw apparatus lead directly into the rings of contractile tissue of the sphincter esophagi. Despite these complex connections, the upper tooth plates can move independently, while the lower tooth plates are more limited by being joined anteriorly by a band of connective tissue.

The first layer of muscles fibers, the transversus dorsalis, originates from the esophagus and inserts on and covers the fourth pharyngobranchial and fourth epibranchial. These muscle fibers run from the esophagus and attach along the dorsal surfaces of the upper pharyngeal jaws, giving the impression that the pharyngeal jaws are encased in an esophageal tube. In muraenines, there is a very elongate bundle of muscle fibers that runs from the posterior part of the fourth epibranchial to the ventral side of the vertebral column and attaches onto the 10th and 14th vertebrae. We call this muscle the dorsal retractor. The dorsal retractor is absent in uropterygiines.

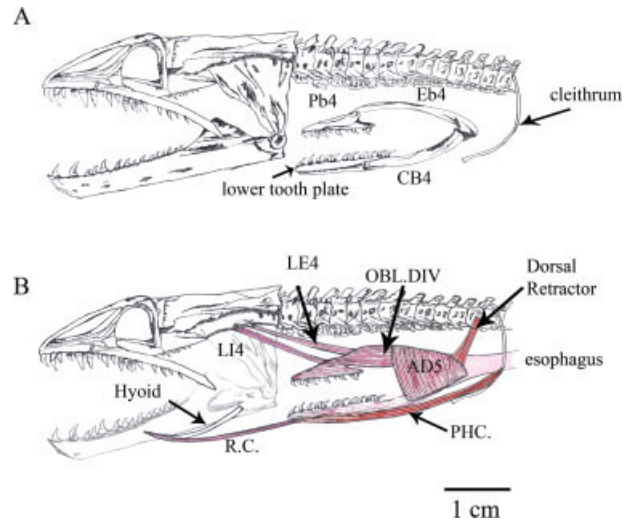


Fig. 6. The neurocranium and pharyngeal jaws of the general muraenine condition in lateral view with first to third gill arches removed. **A:** A lateral view of the skull with the pharyngeal jaw elements labeled. **B:** A lateral view of the skull with the pharyngeal jaw and muscular attachments. The hyomandibula and posterior part of the medial side of the dentary are lighter in color to show the ventral muscular attachments to the skull. A: Pb4, 4th pharyngobranchial; Eb4, 4th epibranchial; Cb4, 4th ceratobranchial. B: LI4, 4th levator internus; LE4, 4th levator externus; OBL.D.IV, obliquus dorsalis IV; R.C., rectus communis; P.C., pharyngocleithralis.

Ventral muscles. The protractor hyoideus connects the hyoid bone to the lower jaw. The anterior fibers of the protractor hyoideus connect to the medial side of the dentary near the mandibular symphysis. The posterior attachment site is the anterior part of the hyoid. The rectus communis connects from the hyoid arch to the anteroventral margin of the pharyngeal tooth plate. The pharyngocleithralis, which is not subdivided into external and internal sections, originates on the dorsal surface of the cleithrum and inserts onto the lateral groove on the lower tooth plate that overlaps the fourth ceratobranchial in muraenines. In uropterygiines, there is no lateral groove on the lower tooth plate that acts as a site of insertion for the pharyngocleithralis. Rather, the pharyngocleithralis originates on the dorsal surface of the cleithrum and inserts onto the ventral side of the anterior part of the lower tooth plate.

Kinematics of Prey Transport

As noted in an earlier study (Mehta and Wainwright, 2007a), *Muraena retifera* capture prey by direct biting. In this study, prey capture ranged from 0.08 to 1.71 s. After prey capture, morays initiated prey transport behavior by ventrally flexing their head, while simultaneously advancing the postcranial portion of their body (see Fig. 7). This movement, which shortens the distance between the posterior part of the branchial basket and the

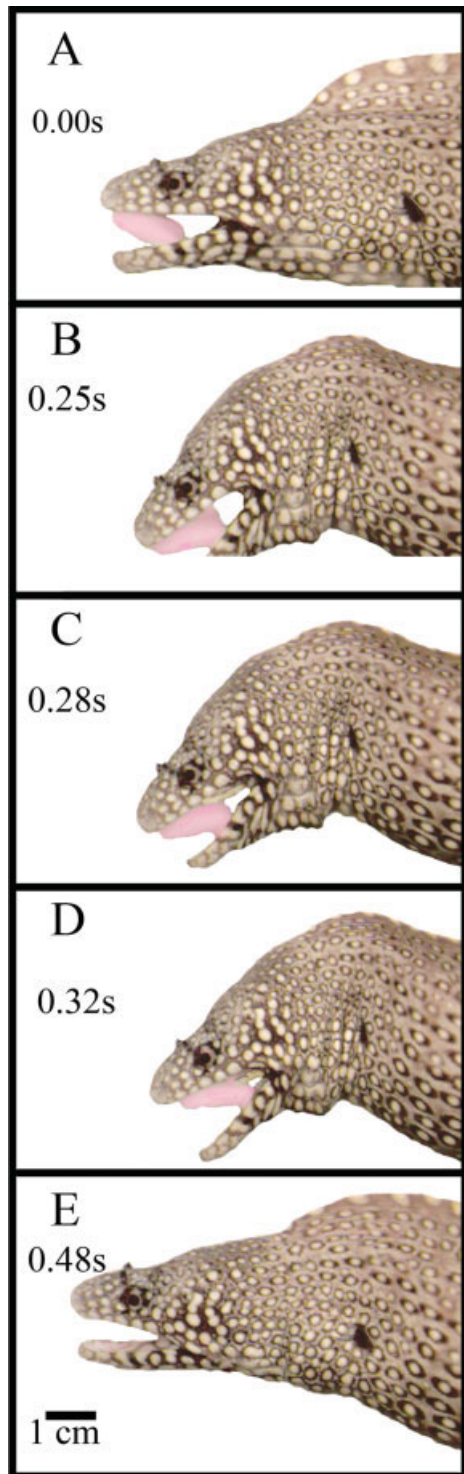


Fig. 7. A–E: Representative sequence of a single capture/transport cycle in *Muraena retifera* beginning with prey capture. Images were taken from video recorded at 100 fps. **A:** Prey capture (0.00 s). **B:** Ventral flexion of the head and slight head retraction. During this time the pharyngeal jaws are protracting (25 s). **C:** Pharyngeal jaws have been protracted into the oral cavity and make contact with prey (28 s). **D:** Pharyngeal jaws bite the prey, while the oral jaws release the prey (32 s). **E:** Moray advances body to swallow prey, while the pharyngeal jaws retract prey into the esophagus (48 s).

oral cavity seems to assist protraction of the pharyngeal jaws between the dentaries and into the buccal cavity. As a result of pharyngeal protraction, there is noticeable ventral displacement (Fig. 7B–D). On the basis of the anatomy of the pharyngeal jaw apparatus, its connections to the dentary, and the extensive reduction of the hyoid apparatus, we inferred that this displacement was caused by the lower pharyngeal jaw during protraction.

On average, the upper pharyngobranchial tooth plates were protracted into the oral cavity 0.58 s after prey capture. We observed the upper pharyngobranchials snag prey in the oral cavity in 81% of our sequences. Once the pharyngeal jaws engaged the prey item, the oral jaws released their grip by increasing their gape distance, allowing the pharyngeal jaws to retract with the prey item towards the esophagus (Fig. 7D). During pharyngeal jaw retraction, eels either stayed in place while the prey disappeared farther into the pharynx or they advanced their body over the prey. The pharyngeal jaws dragged prey into the esophagus at a rate of $10.32 \text{ cm}^{-1}\text{s}$. In addition to *Muraena retifera*, we examined the prey transport kinematics of three other muraenines: *Echidna nebulosa*, *Echidna rhodochilus*, and *Gymnothorax funebris*. Of the four species of eels for which we were able to observe capture and transport behaviors, the upper pharyngobranchial was observed contacting prey for only *Muraena retifera* and *Gymnothorax funebris*. During prey transport, anterior movement of the branchial arch region, ventral displacement, and ventral rotation of the neurocranium of the other two morays, *Echidna nebulosa* and *Echidna rhodochilus* were observed. These kinematic behaviors presumably translated to protraction of the pharyngeal jaw apparatus, although we never observed the pharyngeal jaws making contact with the prey in the oral cavity, presumably because this event took place posterior to the jaw joint and hence out of lateral view.

Contrasting the Kinematics of Capture and Transport

Prey capture and transport in morays exhibit functionally homologous behaviors in that both phases of feeding involve biting. Therefore, we were able to contrast the kinematics for these two phases of feeding. Mean values for kinematic variables measured and results from statistical analyses are presented in Table 2. While peak gape involves elevation of the neurocranium and depression of the lower jaw, it serves different functions during prey capture and transport. These functional differences result in dramatic differences in the timing of peak excursion events (Table 2). During prey capture, peak gape functions to prepare the upper and lower jaws to deliver a forceful bite

TABLE 2. Mean and standard errors of kinematic variables during prey capture and transport

Variables examined	Capture	Transport	F-ratio ^a
Jaw rotation (deg)	15.43 ± 0.78	16.2 ± 1.22	0.31*
Cranial elevation (deg)	9.29 ± 0.86	8.73 ± 0.81	0.002
Peak jaw excursion time (s)	0.50 ± 0.05	0.87 ± 0.08	18.3**
Peak head excursion time (s)	0.45 ± 0.04	1.02 ± 0.08	21.22**
Peak gape distance (cm)	1.58 ± 0.04	1.81 ± 0.06	0.04
Peak gape time (s)	0.58 ± 0.06	1.52 ± 0.10	47.2**
Capture time (s)	0.75 ± 0.06	0.79 ± 0.09	6.4
Ventral displacement (cm)	0	0.45 ± 0.02	186.24**
Ventral displacement time (s)	0	0.93 ± 0.08	69.35**
Over all time (s)	0.69 ± 0.52	1.82 ± 0.36	17.4**
Head retraction distance (cm)	N/A	1.16 ± 0.09	N/A
Cranial excursion during head retraction (deg)	N/A	5.33 ± 1.62	N/A
Pharyngeal jaw protraction distance (cm)	N/A	3.31 ± 0.23	N/A
Prey movement distance (cm/s)	N/A	1.73 ± 0.81	N/A

^aReflects Bonferroni corrected level of significance at * $P = 0.05$, ** $P = 0.001$.

and precedes the prey capture event, while during prey transport, increasing the oral gape functions to release the prey for swallowing. Angular excursions of the head and lower jaw reached similar values in both behaviors as did gape distance (Table 2). Ventral flexion of the skull did not occur until the transport phase of feeding. Overall, prey capture was significantly quicker than prey transport ($F_{1,40} = 17.2$, $P < 0.001$).

A principal components analysis of capture and transport kinematics reveals that PC1 (accounting for 36% of the variation), separates the two behaviors in kinematic space (see Fig. 8). All timing variables loaded positively on PC1 (Table 3). PC2 explained 18% of the kinematic variation and was most strongly correlated with degree of angular excursion, gape distance, and ventral displacement.

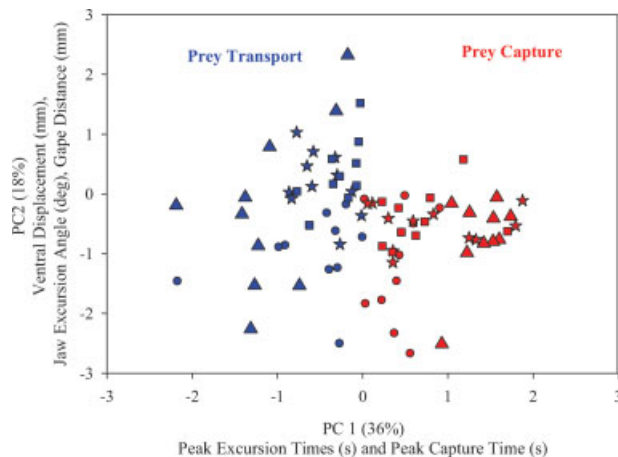


Fig. 8. Axes of kinematic variation in prey capture and transport as revealed by PCA. Each point represents a feeding sequence on the respective axes for the species examined. Note the separation of prey capture (red) from prey transport (blue) on PC1. PC1 was positively correlated with all timing variables (Table 3). PC2 explained 18% of the variation and the variables that loaded strongly on PC2 were cranial and jaw excursions, ventral displacement, and gape distance. Symbols represent individuals of *Muraena retifera*.

Functional Interpretation

On the basis of the anatomy, morphology, kinematics, and videofluoroscopy of the pharyngeal jaw apparatus, we present a functional hypothesis of pharyngeal jaw movements during prey transport in *Muraena retifera* (see Fig. 9). We have identified three distinct phases in moray prey transport behavior: Pharyngeal protraction, pharyngeal-prey contact, and pharyngeal retraction. We begin our schematic with the pharyngeal jaw apparatus “at rest” (Fig. 9A) and end with the prey transported through the pharynx and the onset of peristalsis (Fig. 9D).

Pharyngeal protraction phase. Once the oral jaws have seized the prey item, *Muraena retifera* ventrally flexes the anterior part of its neurocranium (Fig. 9B). Ventral flexion of the neurocranium is followed by anterior movement of the branchial region. As noted earlier, pharyngeal jaw protraction begins with the eel flexing its head and simultaneously advancing its body, a behavior that takes place in 0.52 ± 0.36 s from the onset of prey capture. We propose that during protraction, the fourth branchial levator (dorsal muscle) and the rectus communis (ventral muscle), contract to move the upper and lower pharyngeal jaws into the oral cavity. Contraction of the rectus communis produces a bulge in the ventral side of the skull directly posterior to the position of the hyoid (Fig. 9B). Contraction of muscle fibers that span the

TABLE 3. Loadings of the kinematic variables measured for prey capture and transport on the first two principle components

Variables	PC 1 (36%)	PC2 (18%)
Peak jaw excursion	-0.06	0.57
Peak cranial excursion	-0.18	0.61
Time to peak jaw excursion	0.83	0.18
Time to peak head excursion	0.84	0.25
Time to peak gape	0.77	-0.17
Capture time	0.76	-0.27
Ventral displacement	0.25	0.65
Ventral displacement time	0.72	0.32

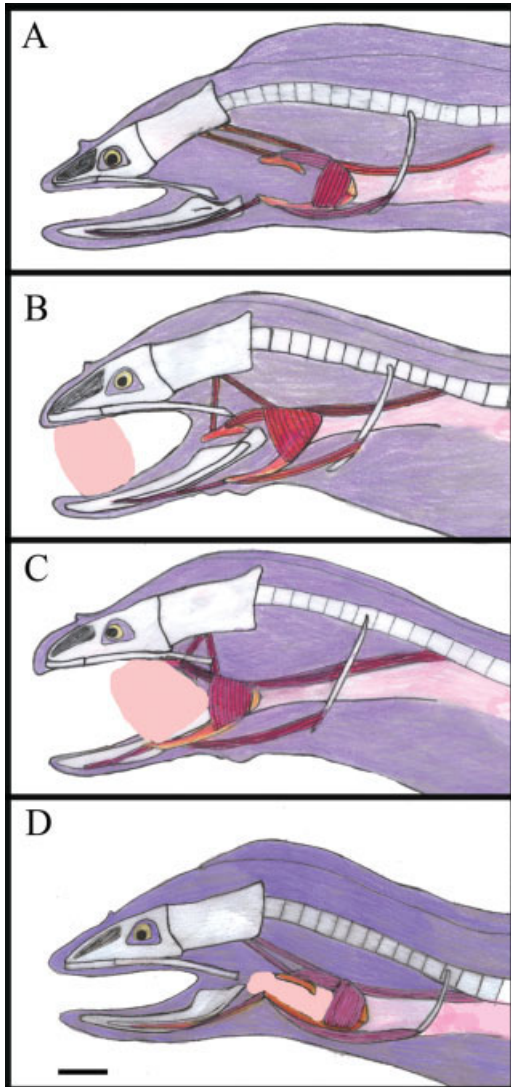


Fig. 9. Schematic representation of the functional morphology of the pharyngeal jaws during prey transport in *Muraena retifera*. **A:** Pharyngeal jaw apparatus fully retracted "at rest." **B:** Pharyngeal protraction phase. The oral jaws have seized the prey item and *Muraena retifera* ventrally flexes the anterior part of its neurocranium. Protraction of the pharyngeal jaws is taking place. **C:** Pharyngeal-prey contact phase. The upper pharyngobranchials are protracted further into the oral cavity. Contraction of the 4th levator internus and obliquus dorsalis dorsally rotates the upper pharyngobranchial at the epibranchial/pharyngobranchial joint so the recurved pharyngeal teeth can penetrate the body of the prey. **D:** Pharyngeal retraction. Prey movement takes place after pharyngeal jaw contact. Contraction of the dorsal retractor retracts the upper pharyngeal jaw, while contraction of the pharyngocleithralis retracts the lower pharyngeal jaw. Pharyngeal jaws are retracted and the prey is transported into the esophagus by peristalsis. Scale bar = 1 cm.

dorsal uppermost arm of the cleithrum and the epaxialis (possible subdivisions of the dorsal retractor), help move the cleithrum anteriorly, which may further aid in protraction of both upper and lower pharyngeal jaws. Because it is attached to the posteriormost branchial arches, the esophagus

also stretches and protracts with the pharyngeal jaw apparatus. As the pharyngeal apparatus moves between the posterior end of the medial sides of the dentaries, the fourth epibranchial adducts toward the fourth ceratobranchial by contraction of the fifth branchial adductor. A lateral view of two feeding sequences using videofluoroscopy revealed that pharyngeal adduction reduced the gape of the pharyngeal jaws by roughly [1/2].

Pharyngeal-prey contact phase. As the upper pharyngobranchial is protracted further into the oral cavity, contraction of the fourth levator internus and obliquus dorsalis dorsally rotate the upper pharyngobranchial at the Pb4/Eb4 joint. The pharyngobranchial can be dorsally rotated up to a 45° angle (Fig. 9C). The dorsal rotation of the fourth pharyngobranchial orients the recurved pharyngeal teeth to penetrate the body of the prey. The rectus communis is fully contracted during this stage and pulls the lower tooth plates further into the oral cavity. At this point, the pharyngeal jaws have achieved their widest gape. After peak pharyngeal gape is attained, the levator internus, the obliquus dorsalis, and the rectus communis relax as the fifth adductor contracts to adduct the upper and lower jaws, resulting in the second bite.

Pharyngeal retraction. Prey movement takes place roughly 0.04 s after pharyngeal jaw contact. For prey movement to occur, the pharyngeal jaws must retract, making prey movement and pharyngeal retraction simultaneous (Fig. 9C). Contraction of the dorsal retractor retracts the upper pharyngeal jaw, while contraction of the pharyngocleithralis retracts the lower pharyngeal jaw. During retraction, the fifth adductor continues to contract for the fourth epibranchial and fourth ceratobranchial to remain adducted so there is a constant grip on the prey. Esophageal and epaxial contraction presumably aid in pharyngeal retraction. Epaxial muscle fibers attaching to the cleithrum assist by moving the cleithrum back towards the resting position. The videofluoroscopy sequence revealed that once the pharyngeal jaws were returned to the resting position, peristalsis in the esophagus moves prey further into the stomach. Prey is transported from the oral cavity into the stomach in as quickly as 1.0 s (Fig. 9D).

DISCUSSION

The existence of a well-developed pharyngeal jaw apparatus in the muraenids has long been recognized (Popta, 1904; Nelson, 1966, 1967). Comparative studies describing the branchial arches and their corresponding muscular attachments have suggested that morays have the most specialized gill arches among the Anguilliformes. From his studies, Nelson (1966, 1967) concluded that the reduction in branchial structures, the enlargement of the pharyngeal jaws and their muscular attach-

ments enable morays to transport relatively large prey into the esophagus. In a recent study, we tested Nelson's hypothesis and confirmed that moray eels have, indeed, evolved an alternative to hydraulic transport, the most commonly used prey transport mechanism in teleost fishes (Mehta and Wainwright, 2007b). The functional data presented in this study also corroborate Nelson's hypothesis; however, we take a more complete and detailed approach in describing this novel prey transport mechanism in morays. We are also in agreement with Nelson's 1966 and 1967 descriptions of the differences in the pharyngeal jaw apparatus between uropterygiines and muraenines.

The original muscle terminology used in earlier descriptions of the origination and insertion sites of the muscles thought to move the pharyngeal jaws in morays has generated much confusion. Anatomical and empirical studies in other actinopterygian fishes have since helped to clarify the musculature of the gill arch region in the Anguilliformes (Winterbottom, 1974; Lauder, 1979; Lauder and Norton, 1980; Springer and Johnson, 2004) and enable us to describe how the muscles associated with the moray pharyngeal jaw system serve to protract and retract the jaws during feeding. Some of these muscles, such as the dorsal retractor, may have evolved independently across teleosts and the homology of these muscles remains difficult to assess.

Muraenines

In all morays examined, the pharyngeal jaw apparatus is located behind the neurocranium and the elongation of the branchial muscles maintains the connection of the pharyngeal jaws with the neurocranium. The levator externus 4 is an important dorsal protractor. We presume that elongation of the levator externus 4 resulted in the synonym protractor posterior (Nelson, 1967). The attachment of the levator externus 4 at a posterior (distal) location on the fourth epibranchial facilitates the extreme jaw protraction distance observed in morays. Contraction of the levator externus 4 pulls the posterior portion of the epibranchial toward its origin on the neurocranium. The upper pharyngobranchial and fourth epibranchial are protracted anterior to the origin of the levator externus 4, resulting in the pharyngeal jaws protruding into the oral cavity. The rectus communis, which connects the hyoid arch to the anteroventral margin of the fourth ceratobranchials, protracts the lower pharyngeal jaw. The elongation of the rectus communis is also associated with the increased distance between the fourth gill arch and the hyoid. Once the pharyngeal jaws are protracted into the oral cavity, they contact the prey with their highly recurved teeth and then bite down on the prey, allowing the oral jaws to release

their grip. This second bite illustrates the novel function of the moray pharyngeal jaw apparatus and calls attention to its interesting structure.

As noted in our earlier study (Mehta and Wainwright, 2007b), the moray pharyngeal jaws resemble elongate, thin grasping arms. The pharyngobranchials and the lower tooth plates are long and thin and bear sharp recurved teeth, which further enables the jaws to grasp prey. The joint between the upper pharyngobranchial and epibranchial enables dorsal rotation of the pharyngobranchial. Contraction of the levator internus 4 positions the recurved teeth in an open orientation for ensnaring prey. The anterior attachment of the left and right lower tooth plates provides a greater surface area for grasping prey. The groove on the lateral side of the lower tooth plate provides a large attachment area for the pharyngocleithralis. Contraction of the pharyngocleithralis, which originates on the dorsal surface of the cleithrum and inserts onto a lateral groove on the fourth ceratobranchials, helps to retract the lower tooth plates.

Uropterygiines

Morays within the subdivision Uropterygiinae appear to exhibit slightly different branchial arch and muscle arrangements compared with those in the Muraeninae, as reported in Nelson (1966, 1967). First, the species we examined, *Uropterygius macrocephalus* and *Anarchias sychellensis*, have ossified hypobranchials in the first and second gill arches. Secondly, the lower pharyngeal tooth plates lie on the dorsal surface of the fourth ceratobranchial. This different site of attachment of the lower tooth plate does not seem to widen the individual tooth plates or provide greater surface area for more teeth. As a result of this dorsal attachment to the fourth ceratobranchial, there is no lateral groove on the lower tooth plate for the attachment of the pharyngocleithralis muscle. Rather, the pharyngocleithralis attaches to the ventral side of the lower tooth plate that hangs freely from the fourth ceratobranchial. The teeth on the pharyngobranchials and lower tooth plate are recurved, although when comparing similarly sized uropterygiines and muraenines, the teeth of the uropterygiine specimens appear to exhibit a larger tooth base. Uropterygiines also have reduced branchial elements and only levator internus 4 and levator externus 4 are well-developed. There is no dorsal retractor that spans the posterior portion of the epibranchial and the vertebral column, suggesting that retraction of the jaws is accomplished primarily by the esophagus and the pharyngocleithralis. Future studies on the pharyngeal morphology of morays belonging to these two groups will shed light on the functional implications of these subtle differences.

Much of what we know of pharyngeal jaw movement has come from studies of perciforms (for review see Wainwright, 2005). Movement in the dorsal–ventral, anterior–posterior, and medial–lateral axis has been inferred from muscle activity patterns and anatomy, and measured with sonomicrometry and cinefluoroscopy. In most cases, the upper jaws have more mobility than the lower jaws. Our anatomical, kinematic, and videofluoroscopy data suggest that the most active axes of movement for the pharyngeal jaws of *Muraena retifera* and *Gymnothorax funebris* are along the dorsal–ventral and anterior–posterior axes. Dorsal–ventral excursions occur during specific times during the protraction and retraction phases and are more variable compared with movements in the anterior–posterior axis. Specifically, dorsal–ventral excursions occur during both the start and end of protraction and retraction (see Fig. 10). During the initial protraction movements both the upper and lower jaws orient dorsally just before beginning their extreme anterior–posterior line of movement. The upper jaws are oriented dorsally when they reach the posterior part of the dentary, while the lower jaws continue with their anterior–posterior line of movement. At this time, the anterior ends of the lower pharyngeal tooth plates are oriented ventrally, which increases the gape between the upper and lower jaws. When contrasted with the oral jaws during prey capture, this is analogous to the “onset” of peak gape in the pharyngeal jaws. At the time of prey contact, the upper jaws adduct towards the lower jaws. Adduction of the upper and lower pharyngeal arms continues throughout most of retraction. Both upper and

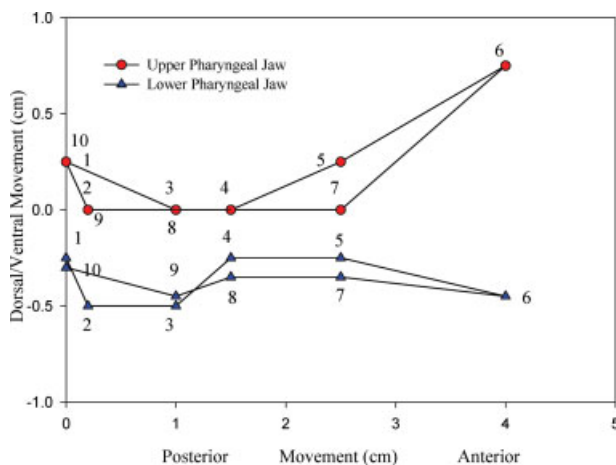


Fig. 10. Two-dimensional movement of the upper and lower pharyngeal jaws of *Muraena retifera* in lateral view. Data were digitized by sequences generated from a single videofluoroscopy event. Note that the motion of the pharyngeal jaws is from posterior (behind the skull) to anterior (inside the mouth cavity). At step 6, the upper and lower tooth plates are inside the oral cavity and fully abducted, representing peak gape.

lower jaws first move in the ventral direction once the prey has been grasped and then retract together, moving posteriorly until they reach the resting position behind the neurocranium. When the pharyngeal jaws are close to their resting position, the upper and lower pharyngobranchials release the prey. Contraction of muscles of the sphincter esophagi and surrounding esophageal muscles propel the prey further into the esophagus.

Kinematics of Biting During Transport

The kinematics of transport in morays are much slower than prey capture kinematics. Angular excursions of the oral jaws are similar in both behaviors, although peak excursion times are different. Peak excursions of the oral jaws prepare the fish to deliver a bite during prey capture, while they function to aid in prey movement during transport. Interestingly, the variance in peak oral gape distance is three times greater during prey transport and gape distance is strongly correlated with prey size during both capture ($r^2 = 0.62$) and transport ($r^2 = 0.83$).

The kinematics of capture and transport of *Muraena retifera* differ from the capture and transport kinematics of a strong suction feeding fish such as the bluegill, *Lepomis macrochirus*. In the bluegill, cranial excursion varies between prey capture and transport although hyoid displacement is the same (Gillis and Lauder, 1995). In addition, bluegills transport prey more rapidly than they capture prey, a trend also observed in aquatic salamanders (Reilly and Lauder, 1990, 1991).

We were able to observe the prey transport behavior of four moray species: *Muraena retifera*, *Gymnothorax funebris*, *Echidna nebulosa*, and *Echidna rhodochilus*. Although all morays exhibit ventral flexion of the head, anterior to posterior movement of the branchial basket, and ventral displacement of the skull during the prey transport phase, only the pharyngeal jaws of *Muraena retifera* and *Gymnothorax funebris* were observed making contact with prey in the oral cavity. Whether there are true interspecific differences in protraction distance of the pharyngeal jaw apparatus is unclear from our observations. However, we speculate that dietary specialization in morays may affect prey transport behavior along with the underlying morphology of the feeding apparatus. *Muraena retifera* and *Gymnothorax funebris* are piscivores, while species of the genus *Echidna* are mostly durophagous (Randall, 1985; Myers, 1991). Durophagous species have blunt rather than preyed dentition in their oral jaws for processing prey (see Fig. 2). These species are consuming prey fragments. Cleared and stained specimens did not reveal any morphological differences in the pharyngeal jaws across muraenines. All muraenines exhibited long and slender epibranchial and

ceratobranchial elements and long, thin tooth plates with recurved teeth. There were differences in the location of the pharyngeal jaws across species. The pharyngeal jaws of *Gymnomuraena zebra* are located below vertebrae 7, while those of *Echidna catenata*, *Echidna nebulosa*, and *Echidna rhodochilus* are located below vertebrae 8. The piscivores had their pharyngeal jaws below vertebrae 9, 10, and 13, in the extreme case of *Rhinomuraena quaesita*. The oral jaws of the durophagous *Gymnomuraena* and species of *Echidna* are also much shorter than those of piscivores, suggesting that the pharyngeal jaws of durophagous morays may not need to protract as far into the oral cavity to grasp prey.

Comparisons With Other Elopomorphs

Nonanguilliform elopomorphs of the genera *Megalops*, and *Elops* exhibit the generalized teleost condition in terms of placement and musculoskeletal elements that comprise the gill arches. In these genera, the dorsal portion of the branchial basket is connected to the neurocranium by branchial levator muscles (Vandewalle et al., 2000), while the ventral portion of the branchial basket is connected to the basihyal of the hyoid apparatus. Within the anguilliforms, there is much variation in both branchial basket structure and distance of the branchial arches to the neurocranium (Nelson, 1966). Despite this variation, the dorsal connection of the branchial basket to the neurocranium is maintained through the branchial levators (Nelson, 1967). However, there seems to be much variation in how the ventral part of the pharyngeal jaw apparatus is connected to the skull (R. Mehta, pers. obs).

The pharyngeal jaw apparatus of morays is modified to move large distances especially when contrasted with the pharyngeal jaws of *Anguilla rostrata*, an anguilliform that is known to use suction during prey capture and transport (Helfman and Clark, 1986; Mehta and Wainwright, 2007a) or with *Moringua edwardsii*, another anguilliform fish that shares comparable gill arch displacement with morays. With the exception of the third basibranchial, which connects the second branchial arch to the third branchial arch, all of the bony elements of the branchial basket are present in *Anguilla* (Nelson, 1966). Although the gill arches of *Anguilla* species are also posteriorly placed, the branchial basket is not as far behind the neurocranium when compared with the moray genera examined. Also, the branchial basket of *Anguilla* sp. is bracketed by the hyoid and pectoral girdle as observed in other nonanguilliform elopomorphs. The pectoral girdle seems to limit posterior placement of the pharyngeal jaws across elopomorphs. In *M. edwardsii* the extreme reduction in the pectoral girdle has favored the muraenid condition and

the gill arches of *Moringua* sp. are posteriorly displaced. However, *M. edwardsii* does not exhibit the extreme reduction in gill arch elements observed in the muraenid condition. The first basibranchial is present and ossified while the second is present, although cartilaginous. Basibranchial 3 and 4 are absent. The hypobranchials of the first and second gill arches are ossified, while the third is cartilaginous. Lastly, the pharyngeal jaw is not as well-developed as in morays, suggesting that their pharyngeal jaws do not share the same functional role.

In members of the Muraenidae there are some unusual features of the ventral and dorsal branchial musculoskeletal elements that may have been associated with the novel function of their pharyngeal jaw apparatus. The reduction of the first to third branchial elements, the hyoid apparatus and the pectoral girdle may have promoted the increase in pharyngeal mobility. The first to fourth branchial arches often articulate with one another and are stabilized by muscular connections among them and to the larger skeletal elements surrounding them, such as the pectoral girdle and the hyoid. Thus, the loss and reduction of surrounding structures and their associated muscular connections may have freed the pharyngeal jaws, further enabling mobility in the anterior–posterior axis. Our limited examination of the external and internal muscles that interconnect gill arches 1–4 suggests that these internal branchial connectors are designed to compress and protract arches 1–3. Compression and protraction of the anterior gill arches occur during pharyngeal jaw protraction and serve to increase the area behind the neurocranium to make room for the pharyngeal jaws. In addition, many muraenids have very loose skin around the branchial region, which enables the pharyngeal region to greatly expand (Böhlke et al., 1989).

Is the Moray Pharyngeal Innovation an Adaptation for Consuming Large Prey?

The general body plan of anguilliform eels is described as elongate with a reduced cross-sectional area (Robins, 1989). The neurocranium is also elongate and narrow. Elongation and narrowing of the skull and body of eels have secondarily increased the distance from the oral jaws to the pharyngeal jaws and esophagus. These characters have been suggested as adaptations for a crevice-dwelling lifestyle (Nelson, 1966). In morays, the reduced hyoid bone and sternohyoideus muscle present a challenge for moving prey from the oral jaws to the pharyngeal jaws (Mehta and Wainwright, 2007b). In lieu of hydraulic transport, which normally involves hyoid depression, morays exhibit extreme mobility in their pharyngeal jaw apparatus in the anterior–posterior axis, enabling

them to transport prey large distances without the use of suction. For morays to transport prey from the oral jaws into the esophagus, the pharyngeal jaw musculature has been modified. The elongation of the dorsal and ventral muscles and their distal points of insertion are important to the functional morphology of the moray pharyngeal jaw system and their elongation has resulted in the ability to protract the pharyngeal jaws from behind the skull into the oral cavity (Figs. 7 and 9).

Although other clades of anguilliforms contain species that have lost their pectoral fins, morays are the only group of anguilliforms whose members have universally lost the pectoral fins (Nelson, 2006). The pectoral girdle of morays has been reduced to a threadlike cleithrum and supercleithrum, which are located behind the fourth gill arch (Fielitz, 2002). It appears the extreme reduction in the pectoral girdle has released constraints on pharyngeal jaw position for many anguilliforms. The reduction in the first to third branchial arches in morays, particularly the loss of the ventral connections made by the basibranchials and hypobranchials, has enabled anterior mobility of the fourth gill arch. The reduction of the cleithrum has also increased intercleithral space, which is known to affect the prey size a predator can consume (Werner, 1974).

One of the most distinct features of morays is their extremely elongate body. However, previous studies of feeding in other elongate predators with reduced cross-sectional areas that belong to disparate teleost groups reveal that elongation does not necessarily lead to alternative feeding mechanisms and prey transport modes (*Anguilla rostrata*: Mehta and Wainwright, 2007a; *Gymnallabes typus*: Van Wassenburgh et al., 2007; *Mastacembalus armatus*, R. S. Mehta pers. obs.). Irrespective of body habitus, biting and suction production are not mutually exclusive functions of the skull and recent empirical work has shown that strong biters are often able to produce suction (Van Wassenburgh et al., 2007). Why then have morays evolved an alternative prey transport strategy?

Moray eels are large predators that hunt in confined spaces. As already noted, there are other teleost groups that contain members with extremely elongate bodies; however, none approach morays in standard length. Morays can attain lengths of up to 3.9 m. A long body coupled with a reduced cross-sectional area magnifies the effects of gape constraints and a long and skinny predator must sustain itself efficiently. The diets of most moray species comprise crustaceans, octopus, and relatively large fish (Chave and Randall, 1971; Yuki-hira et al., 1994; Young and Winn, 2003). The absence of gill rakers on the gill arches suggests that morays swallow prey that are too large to escape between the gill arches, a characteristic of many piscivores (Helfman et al., 1997; Nelson 2006). The

reduction of the pectoral girdle and the loose skin around the branchial region enables the branchial area of morays to expand, presumably allowing large prey to pass through the intercleithral space into the esophagus. The pharyngeal jaws are slender structures that can be compressed when the fifth adductor contracts. The long and slender skeletal elements, the fourth epibranchial and ceratobranchial, are presumably lighter in mass and videofluoroscopy sequences revealed that this structural configuration enables the pharyngeal jaws to move quickly anteriorly into the oral cavity to grasp prey. The caniniform and recurved teeth in both the oral and pharyngeal jaws also appear to be adaptations for grasping and holding onto large struggling prey.

Suction feeding enables aquatic vertebrates to draw prey into their mouths by manipulating the fluid flow surrounding their head. The spatial pattern of this flow is constrained to a region close to the predator's mouth (Day et al., 2005). Given the cranial diversity of suction-feeding fishes and their trophic diversity, suction production seems very versatile. However, suction limits the size of prey a predator can draw into its mouth. While small prey may be easily captured via suction, large prey may easily escape the flow field in front of a moray's mouth (Mehta and Wainwright, 2007b). In addition, large dorsal and ventral excursions and lateral abduction of the neurocranium may inhibit a large predatory fish hunting in the confines of coral reef crevices. Morays seem to have evolved a more effective mechanism for consuming large prey, which works in concert with their hunting strategy of meandering into and through small crevices to find prey.

CONCLUSIONS

From our dissections and examination of cleared and stained specimens it is apparent that significant changes have occurred in the muraenid branchial skeleton, relative to that of other elopomorphs. Studies comparing the gill arch elements and their underlying musculature in anguilliform fishes revealed that the muraenids are highly specialized (Nelson, 1966, 1967). Nelson (1966, 1967) also noted morphological distinctions of the gill arch region between the two muraenid groups: Uropterygiinae and Muraeninae, which we briefly review in this manuscript.

While the upper and lower pharyngeal jaws work together cyclically with a variety of kinematic movements that function to adduct, shear, protract, and retract in perciform taxa (Wainwright, 2005) the pharyngeal jaw apparatus of *Muraena retifera* is specialized for mechanical prey transport. The overall size and shape of the pharyngeal jaw apparatus give the impression of grasping claws rather than the more modest dentition

observed in most teleosts that have been studied previously (Wainwright, 1987, 1989; Gobalet, 1989; Grubich, 2000, 2003; Hulse, 2006). The upper and lower pharyngeal arms are long and thin as are the toothed elements. One of the most striking characters is the highly recurved teeth on both the upper and lower tooth plates (see Fig. 3). These teeth are stout but sharp, enabling them to grab prey. We attribute the hypertrophy of adductor 5 to its role in producing a strong pharyngeal bite.

From the appearance of the pharyngeal teeth, the reduction of anterior gill arch elements, the long retractor and protractor muscles, and a secondarily elongate pharynx, Nelson (1967) speculated that the pharyngeal jaws of morays function to move food from the oral jaws into the esophagus. In an earlier study (Mehta and Wainwright, 2007b), we provided evidence supporting Nelson's hypothesis. Here, we provide the first detailed functional interpretation of the moray pharyngeal jaw apparatus using both anatomy and kinematics. We also identify that there may be kinematic differences across species. The bony elements and the associated muscle attachments underlying the function of the moray pharyngeal jaw apparatus and prey transport behavior are remarkably conserved. The pharyngeal muscles have been reduced, elongated, and enlarged, but they have retained the primitive muscular attachments and basic function. The pharyngeal jaw apparatus of morays reveals how simple changes in structure can permit a functional innovation in an ancient and phylogenetically widespread prey handling system. These innovations in the pharyngeal jaw system of morays, coupled with the reduction in suction capacity, have enabled morays to achieve a unique ecomorphological syndrome, adding to the already remarkable diversity known among teleost fishes.

ACKNOWLEDGMENTS

We thank R.E. Pollard, C. Stafford, T.B. Waltzek, E.R. Wisner for their help with radiographs and videofluoroscopy. D.C. Collar, J.T. Redwine, and E.A. Moffit provided valuable discussion and suggestions. H. Tran provided assistance with photographs.

LITERATURE CITED

- Alfaro ME, Janovetz J, Westneat MW. 2001. Motor control across trophic strategies: Muscle activity of biting and suction feeding fishes. *Am Zool* 41:1266–1279.
- Böhlke EB, McCosker JE, Böhlke JE. 1989. Family Muraenidae. In: Böhlke EB, editor. *Fishes of the Western North Atlantic*. New Haven: Sears Foundation for Marine Research. pp 104–206.
- Chave EHN, Randall H. 1971. Feeding behavior of the moray eel. *Gymnothorax pictus*. *Copeia* 1971:570–574.
- Day SW, Higham TE, Cheer AY, Wainwright PC. 2005. Spatial and temporal flow patterns during suction feeding of bluegill sunfish (*Lepomis macrochirus*) by particle image velocimetry. *J Exp Biol* 208:2661–2671.
- Dingerkus G, Uhler LD. 1977. Enzyme clearing of alcian blue stained whole small vertebrates for demonstration of cartilage. *Stain Technol* 52:229–232.
- Fielitz C. 2002. Previously unreported pectoral bones in moray eels (Anguilliformes: Muraenidae). *Copeia* 2002:483–488.
- Gilbert M, Rasmussen JB, Kramer DL. 2005. Estimating the density and biomass of moray eels (Muraenidae) using a modified visual census method for hole-dwelling reef fauna. *Environ Biol Fishes* 73:415–426.
- Gillis GB, Lauder GV. 1995. Kinematics of feeding in bluegill sunfish: Is there a general distinction between aquatic capture and transport behaviors? *J Exp Biol* 198:709–720.
- Gobalet KW. 1989. Morphology of the parrotfish pharyngeal jaw apparatus. *Soc Integr Comp Biol* 29:319–331.
- Grubich JR. 2000. Crushing motor patterns in drum (Teleostei: Sciaenidae): Functional novelties associated with molluscivory. *J Exp Biol* 9:641–670.
- Grubich JR. 2003. Morphological convergence of pharyngeal jaw structure in durophagous perciform fish. *Biol J Linn Soc* 80:147–165.
- Helfman GS, Clark JB. 1986. Rotational feeding: Overcoming gape-limited foraging in Anguillid eels. *Copeia* 3:679–685.
- Helfman GS, Collette BB, Facey DE. 1997. *The diversity of Fishes*. Malden, Massachusetts: Blackwell Science. 507 p.
- Hulse CD. 2006. Function of a key morphological innovation: Fusion of the cichlid pharyngeal jaw. *Proc R Soc Lond B Biol Sci* 273:669–675.
- Janovetz J. 2005. Functional morphology of feeding in the scale-eating specialist *Cataprinon mento*. *J Exp Biol* 208:4757–4768.
- Konow N, Bellwood DR. 2005. Prey-capture in *Pomacanthus semicirculatus* (Teleostei, Pomacanthidae): Functional implications of intramandibular joints in marine angelfishes. *J Exp Biol* 208:1421–1433.
- Lauder GV. 1979. Feeding mechanisms in primitive teleosts and in the halecomorph fish *Amia calva*. *J Zool* 187:543–578.
- Lauder GV. 1980a. The suction feeding mechanism in sunfishes (*Lepomis*): An experimental analysis. *J Exp Biol* 88:49–72.
- Lauder GV. 1980b. Evolution of the feeding mechanism in primitive actinopterygian fishes: A functional anatomical analysis of *Polypterus lepisosteus*, and *Amia*. *J Morphol* 163:283–317.
- Lauder GV. 1983. Food capture. In: Webb PW, Weihs D, editors. *Fish Biomechanics*. New York: Praeger. pp 280–311.
- Lauder GV, Norton SF. 1980. Asymmetrical muscle activity during feeding in the gar, *Lepisosteus oculatus*. *J Exp Biol* 84:17–32.
- McCosker JE, Randall JE. 2007. A new genus and species of mud-dwelling moray eel (Anguilliformes: Muraenidae) from Indonesia. *Proc Calif Acad Sci* 58:469–476.
- Mehta RS, Wainwright PC. 2007a. Biting releases constraints on moray eel feeding kinematics. *J Exp Biol* 210:495–505.
- Mehta RS, Wainwright PC. 2007b. Raptorial pharyngeal jaws help moray eels swallow large prey. *Nature* 449:79–82.
- Myers RF. 1991. *Micronesian reef fishes*, 2nd ed. Barrigada, Guam: Coral Graphics.
- Nelson GJ. 1966. Gill arches of teleostean fishes of the order Anguilliformes. *Pac Sci* 20:391–408.
- Nelson GJ. 1967. Branchial muscles in representatives of five eel families. *Pac Sci* 21:348–363.
- Nelson JS. 2006. *Fishes of the World*, 4th ed. Hoboken, New Jersey: Wiley.
- Popta CML. 1904. Les arcs branchiaux de quelques Muraenidae. *Ann Sci Nat* 19:367–390.
- Porter HT, Motta PJ. 2004. A comparison of strike and prey capture kinematics of three species of piscivorous fishes: Florida gar (*Lepisosteus platyrhincus*), redfin needlefish (*Strongylura notata*), and great barracuda (*Sphyrna barracuda*). *Mar Biol* 145:989–1000.

- Randall JE. 1963. An analysis of the fish populations of artificial reefs in the Virgin Islands. *Caribb J Sci* 3:31–47.
- Randall JE. 1967. Food habits of reef fishes of the West Indies. *Stud Trop Ocean* 5:665–847.
- Randall JE. 1985. Guide to Hawaiian reef fishes. Newtown Square, PA: Harrowood Books.
- Randall JE, Aida K, Oshima Y, Hoshimoto Y. 1981. Occurrence of a criotoxin and hemagglutinin in the skin mucus of the moray eel. *Lycodontis nudivomer*. *Mar Biol* 62:179–184.
- Reilly SM, Lauder GV. 1990. Metamorphosis of cranial design in the tiger salamander (*Ambystoma tigrinum*): A morphometric analysis of ontogenetic change. *J Morphol* 204:121–137.
- Reilly SM, Lauder GV. 1991. Prey transport in the tiger salamander: Quantitative electromyography and muscle function in tetrapods. *J Exp Zool* 260:1–17.
- Rice WR. 1989. Analyzing tables of statistical tests. *Evolution* 43:223–225.
- Robins CR. 1989. The phylogenetic relationships of the Anguilliform fishes. In: Böhlke EB, editor. *Fishes of the Western North Atlantic*. New Haven: Sears Foundation for Marine Research. pp 9–23.
- Springer VG, Johnson GD. 2004. Study of the dorsal gill-arch musculature of teleostome fishes, with special reference to the Actinopterygii. *Bull Biol Soc Wash* 11:1–260, plates, 205.
- Van Wassenbergh S, Herrel A, Adriaens D, Aerts P. 2007. No trade-off between biting and suction feeding performance in clariid catfishes. *J Exp Biol* 210:27–36.
- Vandewalle P, Parmentier E, Chardon M. 2000. The branchial basket in teleost feeding. *Cybiurn* 24:319–342.
- Wainwright PC. 1987. Biomechanical limits to ecological performance: Mollusc-crushing by the Caribbean hogfish. *Lachnolaimus maximus*. (Labridae). *J Zool* 210:161–178.
- Wainwright PC. 1989. Functional morphology of the pharyngeal jaws in perciform fishes: An experimental analysis of the Haemulidae. *J Morphol* 200:231–145.
- Wainwright PC. 2005. Functional morphology of the pharyngeal jaw apparatus. In: Lauder GV, Shadwick RE, editors. *Fish biomechanics*. New York: Academic Press. pp 77–101.
- Werner EE. 1974. The fish size, prey size, handling time relation and some implications. *J Fish Res Board Can* 31:1531–1536.
- Winterbottom R. 1974. A descriptive synonymy of the striated muscles of the Teleostei. *Proc Acad Nat Sci Philadelphia* 125:225–317.
- Young RF, Winn HE. 2003. Activity patterns, diet, and shelter site use for two species of moray eels. *Gymnothorax moringa* and *Gymnothorax vicinus*, in Belize. *Copeia* 2003:44–55.
- Yukihira H, Shibuno T, Hashimoto H, Gushima K. 1994. Feeding habits of moray eels (Pisces: Muraenidae) at Kuchierabujima. *J Fac Appl Biol Sci* 33:159–166.